

ULTRASONIC EXAMINATIONS OF IMT CHANGES IN COMMON CAROTID ARTERY WALL

Zbigniew TRAWIŃSKI, Tadeusz POWAŁOWSKI, Piotr GUTKIEWICZ

Institute of Fundamental Technological Research
Polish Academy of Sciences
Świętokrzyska 21, 00-049 Warszawa, Poland
e-mail: ztraw@ippt.gov.pl

(received July 15, 2007; accepted October 18, 2007)

The paper describes the initial results of examinations of the intima-media thickness (IMT) in the common carotid artery wall. The examinations of the IMT enable the assessment of elastic properties of the arterial wall. Ultrasonic examinations were carried out on healthy volunteers with the use of the apparatus Vascular Echo Doppler (VED), designed by the authors to measure the elasticity of arteries. Application of the PDA-14 PC-card (Signatec) allowed for the acquisition of ultrasonic RF signal from the output of the apparatus VED and further analysis of dynamic changes of the IMT during a heart cycle. Changing of the IMT in time as a difference between the instantaneous position of the two tracking slopes of RF echoes was obtained. For this purpose, the zero-crossing method for tracking the phase changes of the two rising slopes of the RF ultrasonic echo was used.

Keywords: ultrasound, common carotid artery, elasticity, intima-media thickness.

1. Introduction

The intima-media thickness (IMT) can be identified by the ultrasound measurement as the distance between two parallel echogenic lines at the beginning of the far artery wall, separated by a relatively hypoechoic central region [1, 2]. The IMT is considered as a valuable marker of early atherosclerosis [3–7]. The automated detection of the IMT based on ultrasound M-line signal processing was proposed by HOOKS *et al.* [8] and WENDELHAG *et al.* [9]. New method of detection of the IMT changing, based on the demodulated in quadrature ultrasonic signal, was proposed by HASEGAWA *et al.* [10]. Recently, examination of the change in the IMT of the common carotid artery wall is also very useful in assessing the extent of atherosclerosis in humans [11–13]. This paper presents initial results of ultrasonic measurements of the changes in the IMT, based on the analysis of the RF signal.

2. Method and equipment

The study was carried out by means of a 6.75 MHz ultrasonic apparatus Vascular Echo Doppler (VED) [14], designed by the authors for the purpose of examining the elasticity of arteries, and the 100 MHz, 14-bit Signatec data acquisition card, type PDA-14. 4098-point echoes were memorized in sequences repeated with the frequency of 9 kHz.

The proposed method was verified in laboratory conditions. Laboratory researches were carried out on an elastic pipe. The wall of the pipe consisted of three layers (Fig. 1). The pipe was filled with water, the pressure of which was changed by a hydraulic pump, type Superpump, made by Vivitro Systems Inc. (Canada).

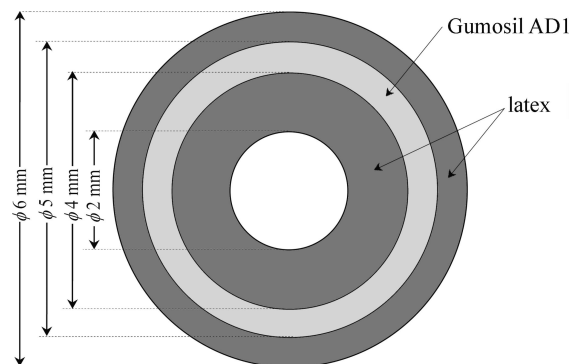


Fig. 1. Cross-section of the elastic pipe.

The frequency of the pump was 1 Hz. During the research, the front surface of the pipe wall was located in the focus of the ultrasonic probe (23 mm). Figure 2 depicts the RF signal of ultrasound echoes coming from the examined elastic pipe. Figure 3 depicts the change in the internal diameter D of the pipe, together with the change in the IMT thickness of the examined pipe's wall. The laboratory examinations show that the measurement system allows to track of the changes in the IMT with accuracy of about $2 \mu\text{m}$ (in water). The common carotid artery wall is composed of three layers: the adventitia, the media and the intima. The basic difficulty in the ultrasonic examination

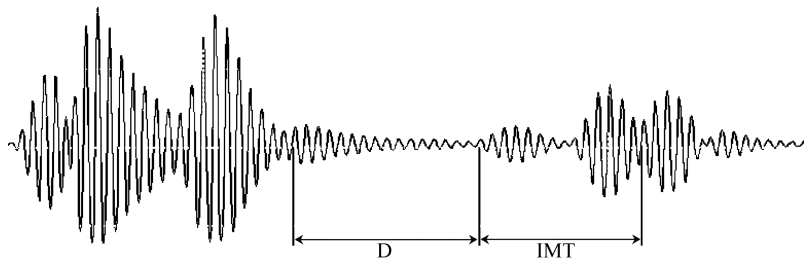


Fig. 2. RF of ultrasonic signal covering the elastic pipe distance. D – diameter of pipe, IMT – intima-media layer of pipe.

of the wall thickness is a limited longitudinal resolution of ultrasonic systems. If the applied transmission frequency is between 5–10 MHz, the longitudinal resolution is from 0.4 to 0.2 mm and is not sufficient to measure the thickness of the intima layer, the dimension of which is less than 0.2 mm.

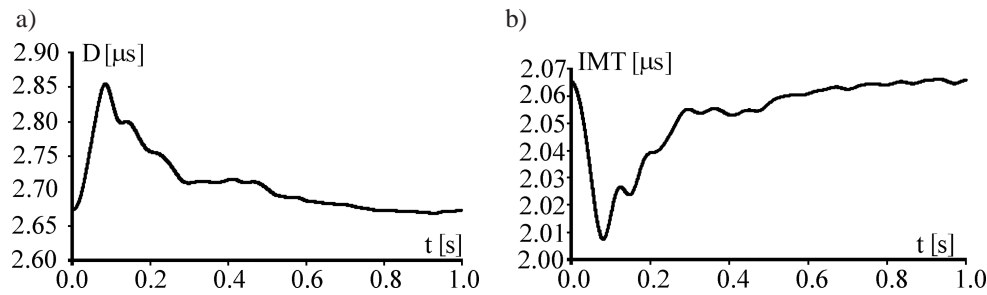


Fig. 3. Diameter wave form (a) and IMT wave form (b) of the elastic pipe. D and IMT are expressed in μs . Values of time correspond with the distance of internal diameter of pipe and the distance of the IMT layer (Fig. 2).

For this reason, the intima-media thickness (IMT) was calculated on the basis of the distance between the two successive echoes, which correspond to the reflection from the intima and adventitia layers respectively. The examination of the IMT was carried out on a group of nine volunteers aged between 22 and 71, without any signs of atherosclerosis in the area of their carotid arteries. The volunteers were examined in lying position and were previously informed about the purpose and the protocol of the research. Their agreement was also obtained for the ultrasonic examination.

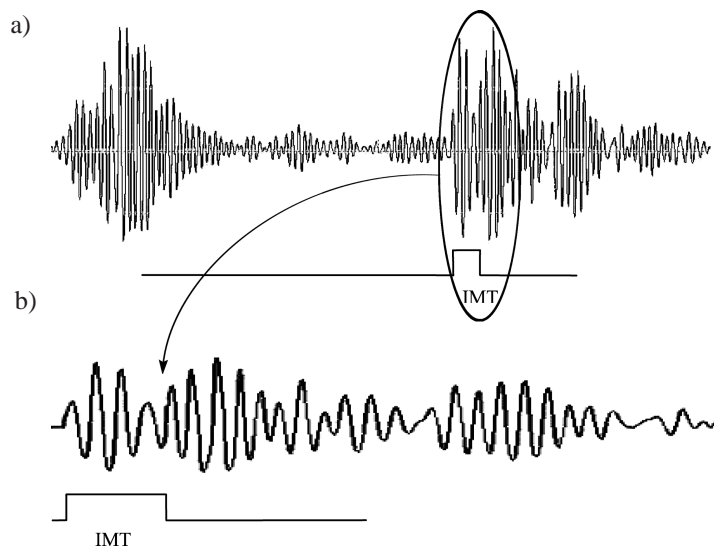


Fig. 4. The ultrasonic RF signal covering the common carotid artery distance (a) and second group of the RF signal (b) coming from the posterior wall of the common carotid artery. Gates indicate the IMT.

The method of defining the IMT thickness of the common carotid artery was based on the detection and tracking of the RF signal area with the help of the zero-crossing method (Fig. 4). It was assumed that the beginning of the IMT layer was the first sharp slope of the ultrasound echo emerging from the echoes coming from the posterior wall. As the end of the IMT layer was assumed the first sharp slope of the echo appearing soon after the local, definite minimum of the echo amplitude, after which the local RF signal became broader. The change in the RF signal was accompanied by a visible change in the phase when the RF signal was close to zero (the IMT measurement is shown through the range gate in Fig. 4).

The analysis of the IMT changes during beating of the heart was carried out on the memorized RF signal using the program created in the Microsoft C++ language. After the initial localization of the IMT layers with the use of cursors, the tracking process of the slopes in the RF signal proceeded, with the use of the zero-crossing method, in the second group of echoes coming from the examined artery (Fig. 4). In this way the instantaneous values of the thickness of the IMT layer were obtained.

3. Results

Average measurement values of relative changes of artery diameter and relative changes of the IMT are given in Table 1.

Table 1. Averaged results of measurements on the examined group.

Number of people	Age [years]	Relative changes of artery diameter [%]	Relative changes of IMT [%]
9	42±16	7.8±2.9	7.4±2.1

The results of measurements and calculations obtained for carotid arteries are given in Figs. 5–7. Figure 5 depicts examples of changes in diameter D of the common carotid artery and its IMT measurement during one heart beat.

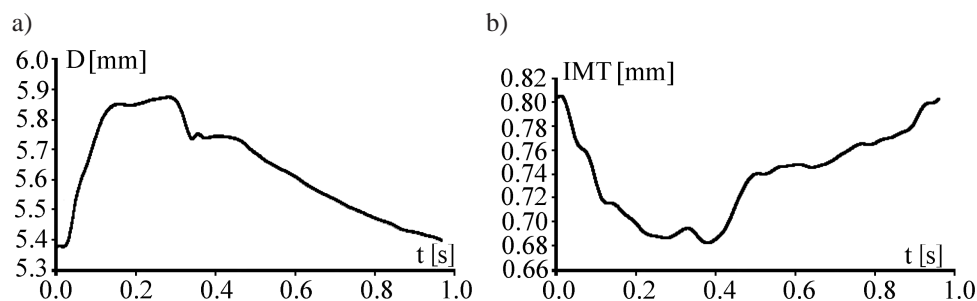


Fig. 5. Diameter wave form (a) and IMT wave form (b) of the common carotid artery of a 30 years old male.

The character of the human IMT shape changes is very close to that obtained by software post-processing, published by CINTHIO *et al.* [15].

Figure 6b depicts the relative change in the IMT of the human common carotid artery wall against the background of hypothetical relation of the relative change in the IMT to age [16]. It is clearly visible on this graph that the relative change in the IMT diminishes with age. The range of the relative changes in the IMT was found to range from 10.6% for young people to 3.68% for older people. The relative change in the IMT of the common carotid artery wall indicates also the association with one of the applied indicators of the arterial elasticity – the logarithmic coefficient of the artery stiffness α introduced by POWAŁOWSKI and PEŃSKO [17].

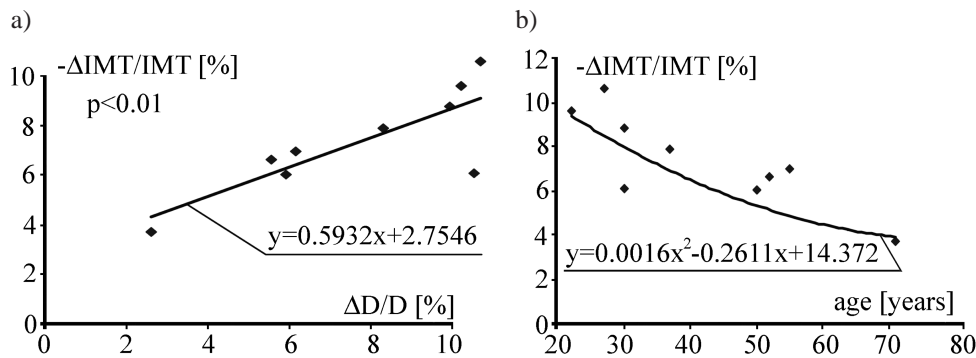


Fig. 6. Dependence between relative change in the IMT: and relative change in the diameter D (a) of the human common carotid artery, and age (b).

Figure 7 depicts the comparison between the examined relative change in the IMT and the logarithmic coefficient of the artery stiffness α .

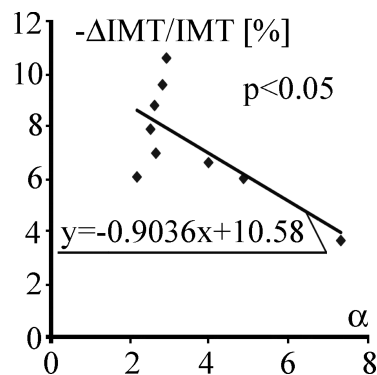


Fig. 7. Dependence between the relative change in the IMT of the human common carotid artery and the coefficient of the artery wall stiffness $\alpha = D_d^2 * \ln(P_s/P_d)/(D_s^2 - D_d^2)$, where D – artery diameter, P – arterial blood pressure, s – systole, d – diastole [17].

4. Conclusion

We have developed a new non-invasive ultrasonic method based on the RF signal analysis, of measuring the intima-media thickness changes during a heart cycle of the far wall in the human common carotid artery. The evaluation shows that the resolution is sufficient for *in vivo* studies. The results confirm the theoretical variation of the IMT changing with age. The relative changes of the IMT is significantly correlated with elasticity of the human common carotid artery wall. The proposed method of measure of the IMT changes might improve the early stage diagnosis of the atherosclerosis, but further investigations are needed.

Acknowledgment

This scientific study was carried out in the period 2005–2007 and was partly sponsored by the research project No. 3 T11E 011 29 of the Ministry of Science and Higher Education.

References

- [1] JAMES E. M., EARNEST F., FORBES G. S., REESE D. F., HOUSER O. N., FOLGER W. N., *High resolution dynamic ultrasound of the carotid bifurcation: a prospective evaluation*, *Radiology*, **144**, 853–858 (1982).
- [2] PIGNOLI P., *Ultrasound B-mode imaging for arterial wall thickness measurement*, *Atheroscler. Rev.*, **12**, 177–184 (1984).
- [3] PIGNOLI P., TREMOLI E., POLI A., ORESTE P., PAOLETTI R., *Intimal plus medial thickness of the arterial wall: a direct measurement with ultrasound imaging*, *Circulation*, **74**, 6, 1399–1406 (1986).
- [4] SALONEN R., HAPPANEN A., SALONEN J. T., *Measurement of Intima-Media Thickness of common carotid arteries with high-resolution B-Mode ultrasonography: Inter and Intra-observer variability*, *Ultrasound in Med & Biol.*, **17**, 3, 225–230 (1991).
- [5] RILEY W. A., BARNES R. W., EVANS G. W., BURKE G. L., *Ultrasonic Measurement of the Elastic Modulus of the Common Carotid Artery. The Atherosclerosis Risk in Communities (ARIC) Study*, *Stroke*, **23**, 952–956, (1992).
- [6] WONG M., EDELSTEN J., WOLLMAN J., BOND M. G., *Ultrasonic-pathological comparison of the human arterial wall. Verification of intima-media thickness*, *Arteriosclerosis and Thrombosis*, **13**, 482–486 (1993).
- [7] SELZER R. H., HODIS H. N., KWONG-FU H., MACK W. J., LEE P. L., LIU CH., LIU CI., *Evaluation of computerized edge tracking for quantifying intima-media thickness of the common carotid artery from B-mode ultrasound images*, *Atherosclerosis*, **111**, 1–11 (1994).
- [8] HOEKS A. P. G., WILLEKES CH., BOUTOUYRIE P., BRANDS P. J., WILLIGERS J. M., RENEMAN R. S., *Automated detection of local artery wall thickness based on M-line signal processing*, *Ultrasound in Med. & Biol.*, **23**, 7, 1017–1023 (1997).

- [9] WENDELHAG I., LIANG Q., GUSTAVSON T., WIKSTRAND J. A., *A new automated computerized analyzing system simplifies readings and reduces the variability in ultrasound measurement of intima-media thickness*, *Stroke*, **28**, 2195–2200 (1997).
- [10] HASEGAWA H., KANAI H., KOIWA Y., *Detection of lumen-intima interface of posterior wall for measurement of elasticity of the human carotid artery*, *IEEE Trans. on Ultras., Ferr. and Freq. Contr.*, **51**, 93–108 (2004).
- [11] MEINDERS J. M., KORNET L., HOEKS A. P. G., *Assessment of spatial inhomogeneities in intima media thickness along an arterial segment using its dynamics behavior*, *Am. J. Physiol Heart Circ Physiol.*, **285**, H384–H391 (2003).
- [12] KANAI H., HASEGAWA H., ICHIKI M., TEZUKA F., KOIWA Y., *Elasticity imaging of atheroma with transcutaneous ultrasound. Preliminary study*, *Circulation*, **107**, 3018–3021 (2003).
- [13] HASEGAWA H., KANAI H., ICHIKI M., TEZUKA F., *Ultrasonic measurement of arterial wall for quantitative diagnosis of atherosclerosis-elasticity imaging of arterial wall and atherosclerotic plaque*, *Rinsho Byori*, Apr; **55**, 363–368 (2007).
- [14] POWAŁOWSKI T., TRAWIŃSKI Z., HILGERTNER L., *Common carotid wall elasticity and intima-media thickness examination by means of ultrasound*, *Archives of Acoustics*, **25**, 205–212 (2000).
- [15] CINTHIO M., JANSSON T., PERSSON H. W., LINDSTROM K., *New non-invasive method for intima-media thickness and intima-media compression measurements*, *Proceedings of the 2005 IEEE Ultrasonic Symposium*, 389–391 (2005).
- [16] TRAWIŃSKI Z., POWAŁOWSKI T., *Modeling and ultrasonic examination of common carotid artery wall thickness changes*, *Archives of Acoustics*, **31**, 4S, 29–34 (2006).
- [17] POWAŁOWSKI T., PEŃSKO B., *A noninvasive ultrasonic method for elasticity evaluation of the carotid arteries and its application in the diagnosis of cerebro-vascular system*, *Archives of Acoustics*, **13**, 109–126 (1988).