

---

**PHARMACOLOGY**

---

**IN VIVO PERFORMANCE OF THE EXPERIMENTAL CHITOSAN BASED BONE SUBSTITUTE – ADVANCED THERAPY MEDICINAL PRODUCT. A STUDY IN SHEEP**

WITOLD BOJAR<sup>1\*</sup>, MARTYNA KUCHARSKA<sup>2</sup>, TOMASZ CIACH<sup>3</sup>, IWONA PAŚNIK<sup>4</sup>,  
ELŻBIETA KOROBOWICZ<sup>4</sup>, KRZYSZTOF PATKOWSKI<sup>5</sup>, TOMASZ GRUSZECKI<sup>5</sup>,  
MAREK SZYMANOWSKI<sup>5</sup> and PRZEMYSŁAW RZODKIEWICZ<sup>6</sup>

<sup>1</sup>Medical Devices Department, National Medicines Institute, Chełmska 30/34, 00-725 Warszawa, Poland

<sup>2</sup>Engineering Laboratory, Faculty of Chemical and Process Engineering, Warsaw University of Technology, Polish Academy of Science, Institute of Fundamental Technological Research, Poland

<sup>3</sup>Biomedical Engineering Laboratory, Faculty of Chemical and Process Engineering, Warsaw University of Technology, Poland

<sup>4</sup> Department of Clinical Pathomorphology, Medical University of Lublin, Poland

<sup>5</sup> Faculty of Biology and Animal Breeding, University of Life Sciences, Lublin, Poland

<sup>6</sup>Department of Biochemistry and Molecular Biology, Institute of Rheumatology, Warszawa, Poland  
Department of General and Experimental Pathology, Medical University of Warsaw, Poland

**Abstract:** When evaluating a novel bone substitute material, advanced *in vivo* testing is an important step in development and safety affirmation. Sheep seems to be a valuable model for human bone turnover and remodeling activity. The experimental material composed with the stem cells is an advanced therapy medicinal product (acc. to EC Regulation 1394/2007). Our research focuses on histological differences in bone formation (guided bone regeneration – GBR) in sheep maxillas after implantation of the new chitosan / tricalcium phosphate / alginate (CH/TCP/Alg) biomaterial in comparison to the commercially available xenogenic bone graft and a/m enhanced with the stem cells isolated from the adipose tissue. Twelve adult female sheep of BCP synthetic line, weighing 60-70 kg were used for the study. The 11 mm diameter defects in maxilla bone were prepared with a trephine bur under general anesthesia and then filled with the bone substitute materials: CH/TCP/Alg, BioOss Collagen, Geistlich AG (BO), CH/TCP/Alg composed with the stem cells (CH/S) or left just with the blood clot (BC). Inbreeding cycle of the animals terminated at 4 months after surgery. Dissected specimens of the maxilla were evaluated histologically and preliminary under microtomography. Histological evaluation showed early new bone formation observed around the experimental biomaterial and commercially available BO. There were no features of purulent inflammation and necrosis, or granulomatous inflammation. Microscopic examination after 4 months following the surgery revealed trabecular bone formation around chitosan based bone graft and xenogenic material with no significant inflammatory response. Different results - no bone recreation were observed for the negative control (BC). In conclusion, the tested materials (CH/TCP/Alg and BO) showed a high degree of biocompatibility and some osteoconductivity in comparison with the control group. Although the handiness, granules size and setting time of CH/TCP/Alg may be refined for future clinical tests. The relevant beneficial influence of using the adipose derived stem cells in GBR was not confirmed in this model.

**Keywords:** alginate, bone substitute material, chitosan, guided bone regeneration,  $\beta$ -tricalcium phosphate, sheep model, stem cells

**Abbreviations:** AI – acute inflammation, Alg – alginate salt, BF – bone formation, BO – BioOss collagen, CH – chitosan, CH/S – experimental material comprised with the stem cells, CH/TCP/Alg – experimental biomaterial, CI – chronic inflammation, F – fibrosis, GBR – guided bone regeneration, GI – granulomatous inflammation, L – lymphoid cells, M – macrophages, N – neutrophils, Ne – necrosis, NV – neovascularization, TB – bone type, TCP –  $\beta$ -tricalcium phosphate

---

\* Corresponding author: e-mail: w.bojar@nil.gov.pl; phone: +48 22 8413689, fax + 48 22 8410652

Guided bone regeneration (GBR) techniques has significantly changed the oral surgery during the last decades. Although the autogenous bone is still considered as the “gold standard” for the bone substitution, there are a wide variety of biomaterials used alternatively.

The basic concept of our project was to design and evaluate the biodegradable and well tolerated by the tissues alloplastic material for the GBR. The basis of this composite material was chitosan – naturally occurring polysaccharide, widely studied in pharmaceutical and nonpharmaceutical applications (1-5). The other components were calcium phosphate salt -  $\beta$ -tricalcium phosphate ( $\beta$ TCP) and solution of alginate salt. The ability of composing chitosan with osteoconductive and osteoinductive substances promised well to synthesize an allograft of desirable properties.

Chitin and its derivatives have been used as scaffolds for bone and other natural tissue regeneration as well as structures by which three dimensional formation of tissues are supported (2, 5, 6). While searching for a proper material for a good scaffold, there are important factors that should be taken into account, like ability to form porous structure for tissue to grow, ability to form resorbable matrix, biodegradability and nontoxic byproducts from the digestion (1, 7). Thus, neither the physical nor biological properties of such biomaterials should be ignored (6, 8). Chitin and its derivatives have been shown to possess these criteria.

Its excellent gel-forming properties and ability to be reshaped into various forms simply by thermally induced separation method strongly enhance its potential applications in the biomedical field. Some researchers also suggested that chitosan has osteoinduction and osteoconduction potentials when used as a bone scaffold material (4, 5).

It is worth to mention that we intentionally chose  $\beta$ -tricalcium phosphate instead of hydroxyapatite as one of the components. Grafting materials with high resorption rates may allow for the formation of bone with no residual graft particles at the time of implant placement and loading (9). However, their capability to sustain alveolar ridge volume in the long term might be inferior to that of mineralized grafts (9).

$\beta$ TCP can also alter morphological structure and degradation behavior of the chitosan. These changes probably are attributed to fact that  $\beta$ TCP could bind with chitosan through ionic bonding, and subsequently crosslinked to the different parts of chitosan polymer chains (4).

Alloplastic materials of those kind are biocompatible and free of the risk of contamination. They

can be manufactured with precisely defined physical and crystalline properties and have a consisted batch quality. There is no need to inform patients about the residual risk of immunological reaction or infection, as in the case of the materials of biological origin (10).

Although in many cases, the method of choice for such a material is its convenient application for surgeons. Advantageous bone graft for oral surgery and general dentistry applications may well be injectable, sculptable and with a controllable setting time. The material we developed seems to fulfill the above mentioned criteria. The recent experiments in rats and cell cultures emboldened us to proceed the research on big animal model (11).

According to many authors, a dog is the most suitable as a model for human bone from a biological point of view (12). However, adult sheep takes the advantage of being more similar to humans in weight and bone dimensions, what allows the implantation of e.g., human prostheses (13). Another important matter is that we used the small ruminants at the end of the breeding cycle. The animals were not sacrificed just for the research but were utilized for goods commonly obtained from sheep breeding.

Notwithstanding the advances in tissue engineering, oral regenerative medicine strategies are still unpredictable for repair tooth-supporting tissues destroyed as a consequence of trauma, chronic infection or surgical resection.

In order to overcome the limitations of routinely adopted biomaterials as allografts, xenografts, and alloplastics in terms of predictability and quality of bone formation and, for example, ability to sustain alveolar ridge morphology over long periods of time, novel tissue engineering therapies have been developed including the delivery of growth factors incorporated in carriers, scaffolds and bone grafts.

Implantation of culture-expanded mesenchymal stem cells has been demonstrated to effect tissue regeneration in a variety of animal models and depends on local factors to stimulate differentiation into the appropriate phenotype (14, 15).

Stem cell research is not a new medical entity by any means. There has been extensive research for many years in the areas of orthopedics, cardiology, neurology and internal medicine. For quite a few years, also the dental surgeons have taken a harder look at stem cells and their use in promoting more predictable bone grafting.

Composing a biomaterial with the stem cells gives rise to the tissue engineering product. According to the EC Regulation 1394/2007 such a

material is then the advanced therapy medicinal product.

## EXPERIMENTAL

### Methods

The evaluated biomaterial – CH/TCP/Alg was designed as a biphasic system, where the solid phase consisted of chitosan (CH) and  $\beta$ -tricalcium phosphate (TCP) particles and the liquid one of a 2% solution of alginate salt (Alg). The injectable system formation relied on calcium ions being released from chitosan/TCP particles into the liquid alginic phase tending to form a gel in the presence of calcium ions.

Chitosan (~95% degree of deacetylation) (3, 16) was purchased from Medical Heppe GmbH,  $\beta$ -tricalcium phosphate from Sigma Aldrich and alginic acid sodium salt from brown algae was purchased from Fluka, Sigma Aldrich, Seelze, Germany. The manufacturing process was described in detail in previous publications (11, 17).

The material was previously evaluated according to the European / Polish Standard PN-EN ISO 10993 *Biological evaluation of medical devices*. The results of the biocompatibility tests were favorable according to expectations and the biological properties of basic materials. The tested material showed its cytocompatibility, with no adverse reactions when in direct contact with living tissues and its extracts were safe for laboratory animals (11, 17).

BioOss Collagen (Geistlich AG, Wolhusen, Switzerland) was chosen as a reference material and a positive control. This xenogenic bone graft is acknowledged among professionals, extensively used and has major long-term success reports (18-22).

BioOss Collagen is comprised of BioOss spongiosa (bovine xenograft) with the addition of 10% highly purified porcine collagen type I. The collagen acts, according to the manufacturer, as a cohesive for the granules.

The Local Committee of the Animal Experimentation Ethics Commission, Poland approved the research protocol.

Twelve female sheep of synthetic BCP line, 3 years old, weighing 60–77 kg were used for the study. The animals were prepared dietetic for the surgery: starvation for 6 h and no access to water for 3 h. Xylazine was used for the intravenous premedication and after 5 min the induction of general anesthesia was administered with a combination of diazepam and ketamine (mixture 1 : 1). The conduction of anesthesia was proceeded with the same

drugs in doses fractionated according to the strength effect.

A local anesthetic (2 mL of 4% articaine with adrenaline 1 : 100000) was administered under the mucosa after the application of topical antiseptic (0.2% chlorhexidine) in the vestibule. A semilunar incision in the region of last upper molars was made and the full thickness flap was detached to expose the bone surface of the maxilla. Eleven millimeters diameter bone defects were prepared with a 10 mm trephine drill (Hager & Meisinger, Neuss, Germany) mounted on a contra-angle handpiece coupled to a surgical motor rotated at 8,000 rpm. The surgical site was continuously irrigated with sterile saline and the undercut bone was elevated with bone curettes or elevators at the depths up to 5 mm. After the implantation, the flaps were sutured with 3/0 braided, absorbable suture material. No membranes were used for the protection of the grafts.

Adipose tissue used to acquire the stem cells to combine them with CH/TCP/Alg was obtained from six sheep a day before the implantation. Under local anesthesia (2% lignocaine) a small incision in the area of the base of the tail was made to collect about 2 g of the tissue. Subcutaneous adipose tissue was placed into falcon tube containing phosphate buffered saline (PBS) supplemented with antibiotics (100 U/mL penicillin and 100  $\mu$ g/mL streptomycin) and transferred to the laboratory. Tissues were purified from blood vessels, weighed and then cut using surgical scissors into small pieces (10–20 mg). Cells were isolated from 0.612 to 3.788 g of adipose tissue with modified method described by Bunnell et al. (23). Collagenase buffer (buffer content: PBS, 100 U/mL penicillin, 100  $\mu$ g/mL streptomycin, 0.15% collagenase) was added to tissue in a ratio of 4 mL of buffer per 1 gram of tissue, transferred into a falcon tube and then incubated at 37°C under continuous shaking for 1 h. Subsequently, DMEM supplemented with 10% FBS, streptomycin and penicillin, was added in ratio 1 : 1 to tube to stop digestion reaction. Cell suspension was then filtered through nylon mesh. The sample was then centrifuged at 1200  $\times$  g for 5 min at room temperature, washed with PBS containing antibiotics and centrifuged again. The pellet was resuspended in 1 mL of erythrocyte lysis buffer and incubated for 5 min in 5°C. After incubation, 5 mL of PBS containing antibiotics was added and probe was then centrifuged. The pellet was resuspended in DMEM supplemented with 10% FBS, streptomycin and penicillin. Live nucleated cells were counted in Bürker chamber after staining with trypan blue. The number of cells isolated per gram of the sheep adi-

pose tissue was  $1.1-2.32 \times 10^5$  cells. Isolated cells were then plated in T25 falc and incubated at  $37^\circ\text{C}$  and  $5\% \text{CO}_2$  overnight. The next day, cells were collected, centrifuged and platelet was suspended with a proportional amount of PBS so that we

received a cell suspension with a concentration of  $1 \times 10^5$  cells/mL. Cell suspension was then mixed with equal volume of  $4\%$  sodium alginate solution. Cell suspension in  $2\%$  sodium alginate was then used for graft formation.

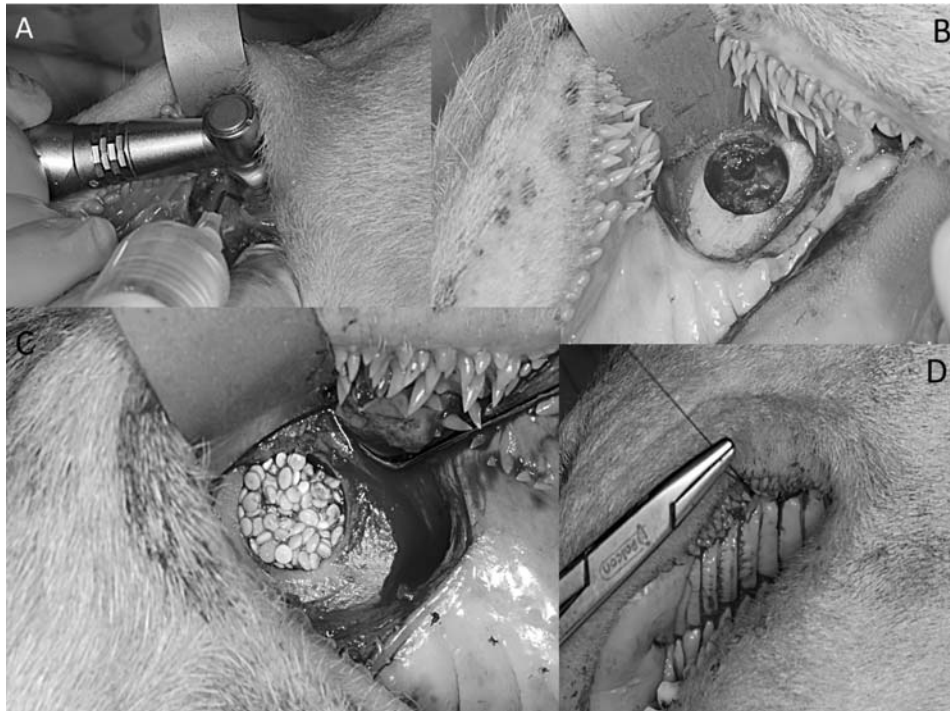

Figure 1. Surgical procedure. **A:** bone perforation with the trephine drill; **B:** 11 mm bone defect in the maxilla; **C:** biomaterial on the place; **D** wound suturing

Table 1. The list of animals.

No.	Sheep No.	Right site	Left site	Body weight [kg]
1	3442.7	BO	BC	64
2	3287.4	BC	BO	69
3	3495.3	CH/TCP/Alg	BC	70
4	3213.3	CH/TCP/Alg	BC	75
5	3348.2	BO	CH/TCP/Alg	75
6	3226.3	BO	CH/TCP/Alg	69
7	3336.9	CH/S	BO	86
8	3398.7	CH/S	CH/TCP/Alg	64
9	3492.2	CH/S	CH/TCP/Alg	64
10	3227.0	CH/S	BO	77
11	3203.4	CH/S	BO	60
12	3337.6	BC	CH/S	77



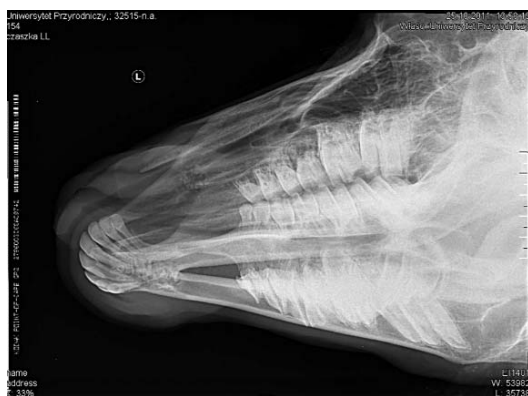

Figure 2. Biomaterial (CH/S) in the sheep maxilla. Radiographic image 2 months following implantation

After rinsing the surgical site and double check of hemostasis, the sheep were transported to the adjacent room for postanesthetic recovery. Intramuscular injection of penicillin-streptomycin was administered to every animal for postsurgical protection.

Eight weeks after implantation, a radiographic control of the surgical sites was performed to evaluate the bone alteration and graft particles distribution. The animals were immobilized for 1-2 min to take the radiographs. The x-rays were taken using portable device and digital scanner, which assured the minimal exposition time. There was no need for anesthesia to perform the procedure.

At 4 months after implantation, the sheep were passed to the abattoir. It is worth to mention that this happened in line with the breeding cycle. The maxillas with overlying skin were collected and fixed in 10% formalin in a phosphate buffer. Some of the specimens were scanned using a micro CT at a resolution of 18  $\mu\text{m}$  to measure dimensions of bone defects and observe the distribution of biomaterial particles.

The tissue samples taken from animals 4 months post-implantation underwent careful histological examination. After decalcification (with Decalcifier II, Surgipath, Richmond, USA), the specimens were processed by routine histological processing using paraffin-embedding method. The sections (4-5  $\mu\text{m}$  thick) were stained with hematoxylin and eosin. The evaluation was performed using light microscope Nikon Eclipse 50i.

The total number of surgical defects were 24 ( $n = 24$ ). The defects were filled with CH/TCP/Alg ( $n = 6$ ), BioOss Collagen (BO) ( $n = 7$ ), CH/TCP/Alg combined with stem cells (CH/S) ( $n = 6$ ) or left only

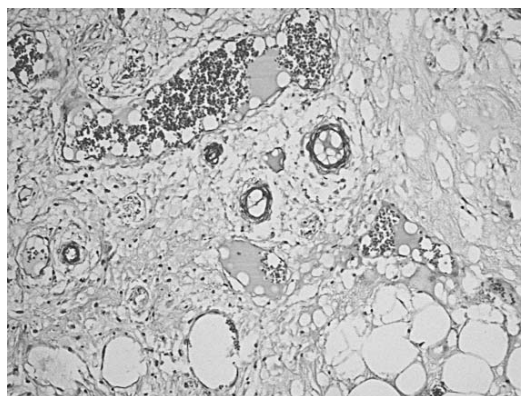


Figure 3. Defect filled with coagulum (BC). Loose and fibrotic connective tissue, adipocytes and small capillaries (100 $\times$ )

with a blood clot (BC) ( $n = 5$ ). Every animal had a different test sample on both sides of maxilla.

The list of animals is shown in Table 1.

## RESULTS

The results of histopathological evaluation were based on the analogical tests on the small animal model (11). The following parameters were evaluated:

- bone formation (scale 0-3);
- type of bone tissue (newly formed / mature);
- feature of acute inflammation (absent, minimal, moderate, severe);
- feature of chronic inflammation (absent, minimal, moderate, severe);
- presence of granulomatous inflammation;
- infiltration of: neutrophils, lymphoid cells, macrophages (0 - absent, 1 - rare: 1 - 5/HPF, 2 - moderate: 5-10/HPF, 3 - heavy, numerous infiltrate: > 10/HPF);
- presence of giant cells (0 - absent, 1 - rare 1-2/HPF, 2 - moderate 3-5/HPF, 3 - extensive >5/HPF);
- fibrosis (scale 0-3);
- necrosis (present, absent);
- neovascularization (present, absent).

The results are presented in a descriptive manner for each animal and each control group because of some problems with systematizing. The trouble with specific evaluation of some cases was due to sheep behavior just after the sedation. The animals started to eat the hay from the floor of recovery room immediately. Starvation after the surgery was not recommended by the veterinary anesthesiologist but in some cases it caused separation of the layers

of the wound and migration of the particles of the grafts. All animals, as assessed by the veterinary, were in a good shape after the surgery, there were no signs of pain or suffering in next few days.

In the defects filled with coagulum (BC – negative control) a moderate fibroblastic alteration was observed in all cases (F 1). In one case there was also a minimal bone formation (BF 1). Neither acute nor chronic inflammation was recorded. There were no signs of neovascularization as well.

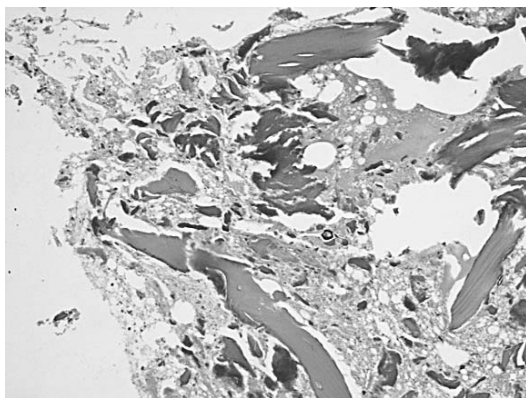


Figure 4. BO. New bone formation with accompanying NV and F (100x)

The commercially available xenogenic material (BO) exhibited different manners. Because of the reasons mentioned above, just six out of seven samples were evaluated. In five cases a woven bone formation was observed (Fig. 2). There was no mature bone features in any of them. In three cases bone formation was rated 1 (scale 0-3), in two cases rated 2. The fibrosis occurred in each sample with BO: minimal in two, moderate in three and extensive in one of the samples. The chronic inflammation with

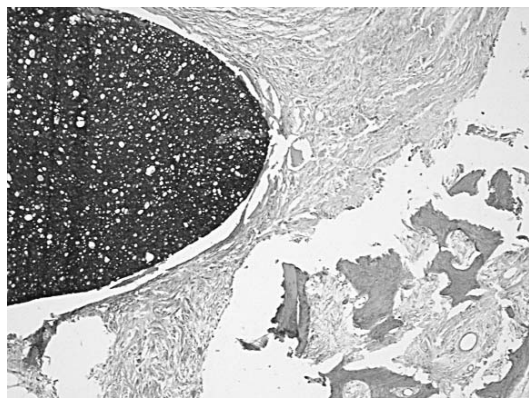


Figure 5. CH/TCP/Alg. Bone formation with accompanying fibrosis (100x)

Table 2. Detailed results of histological tests.

	Right site Material / the most distinctive features	Left site Material / the most distinctive features
1	BO AI 3, GI T, G 2, Ne 3, L 1, M 1, F 2, Ne 1	BC F 1
2	BC BF 1, NB, F 1	BO BF 1, NB, GI T, L 1, F 1, NV 1
3	CH/TCP/Alg BF 1, NB, F 1	BC F1
4	CH/TCP/Alg BF 1, NB, F 1	BC BF 1, NB, F1
5	BO BF 2, NB, F 2	CH/TCP/Alg no data
6	BO no data	CH/TCP/Alg BF 2, NB, F1
7	CH/S BF 1, MB, F 1	BO BF 2, NB, CI 2, F 2
8	CH/S BF 1, MB, CI 1, F 1, NV 1	CH/TCP/Alg BF 1, MB, NB, F 2, NV 1
9	CH/S BF 2, MB, F 2, NV 1	CH/TCP/Alg BF 1, NB, F 2, NV 1
10	CH/S BF 1, NB, MB, F 2, NV 1 B	O BF 1, NB, CI 1, F 2, NV 1
11	CH/S BF 1, MB, CI 1, F 2	BO BF 1, NB, CI 2, GI Y, L 2, F 3, NV 1
12	BC F1	CH/S no data

**BF**, bone formation: 0 – absent; 1 – minimal (single trabeculae); 2 – moderate; 3 – intensive (numerous trabeculae); **TB**, bone type: NB – newly formed, early bone; MB – mature, calcified bone; **AI**, acute inflammation, **CI**, chronic inflammation: 0 – absent, 1 – minimal, 2 – moderate, 3 – severe; **GI**, granulomatous inflammation: Y – yes, present, N – no, absent; **N**, neutrophils, **L**, lymphoid cells, **M**, macrophages: 0 – absent, 1 – rare 1-5/HPF, 2 – moderate 5-10/HPF, 3 – heavy infiltrate >10/HPF; **F**, fibrosis: 0 – absent, 1 – minimal, 2 – moderate, 3 – extensive; **Ne**, necrosis; **NV**, neovascularization: 0 – absent, 1 – present.

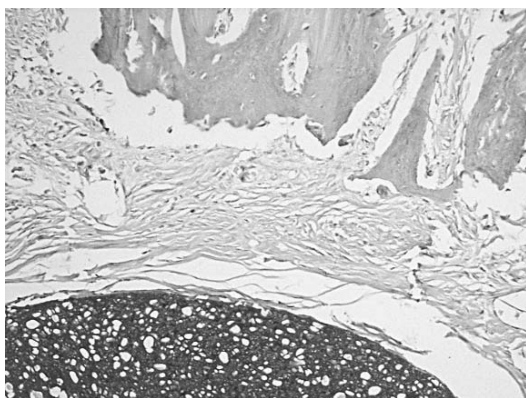


Figure 6. CH/TCP/Alg. Bone formation with accompanying fibrosis (200x)

minimal and moderate intensity was observed in three of six cases. In one of the animals (sheep no. 1) there were signs of acute inflammation (AI 3) with its morphological exponent – heavy infiltration of neutrophils (N 3) and minimal necrosis (1). Sheep no. 11 samples were characterized by a classic chronic inflammation (CI 2) composed with a granulomatous inflammation (GI), extensive fibrosis (F 3) but also new bone formation (NB). In three of six cases neovascularization was listed (NV 1).

The total number of the defects filled with the experimental CH/TCP/Alg and the same material composed with stem cells (CH/S) which were appropriate for microscopic evaluation was 10. Thus, it was not possible to evaluate two of twelve samples.

The typical clinical picture was the formation of newly formed and mature bone in all cases with the moderate fibrosis, F 2 in four and F 1 in six of ten samples.

There were no signs of acute inflammation in any case. The minimal chronic inflammation (CI 1) were present in two samples of CH/S. Neovascularization was observed in five of ten samples.

When evaluating the samples of CH/TCP/Alg (n = 6) in four cases, the newly formed bone was estimated as the woven bone (NB) and in two cases, as a fusion with the mature bone (NB and MB). The biomaterial composed with the stem cells (CH/S, n = 4) gave the evidence of the mature bone in three cases and the mature with the woven bone in one.

The attempt to systematize the results is shown in Table 2.

## DISCUSSION AND CONCLUSION

The histological evaluation of the defects filled with the biomaterials revealed the presence of the

bone remodelling fields with the active osteoblasts and single osteoclasts at the margins. The mesenchymal alteration was characterized by the dynamic foci of bone formation with the osteoblasts participation. The remnants of the CH/TCP/Alg, CH/S and BO particles were present with the fibroblastic remodelling of the implantation sites. There were also visible spots of beginning mineralization with collagenization of the submucosal membrane and osteoblastic reactivity. The differentiation between the experimental biomaterial and positive control (BO) were associated with the disintegration of the particles of CH/TCP/Alg and CH/S, rather than the degree of ossification. The commencing resorption at 4 months after implantation is in compliance with the expectations of its originators.

In case of negative control (BC), the predominant features in histological observations were passive vasocongestion and reactive fibrosis around the minor ossified structures and fibrosis without ossification. There were some single trabeculae (BF 1) in the fields of fibroblastic remodeling in one case (sheep no. 2).

When trying to emphasize the variations between the experimental CH/TCP/Alg and the biomaterial composed with the stem cells (CH/S), it is worth to mention the presence of slightly more mature bone in the defects filled with CH/S. The difference between the result BF 1 and BF 2 are not unequivocal. These test results are undoubtedly introductory in view of problems with the graft retention in the surgical sites and relatively small amount of the samples. It is regrettable that no morphometric analysis was performed in this study.

At this point, it is hard to legitimate the beneficial influence of the adipose derived stem cells in obtained amount composed with graft material for the bone formation. It seems like the number of cells isolated per gram of the sheep adipose tissue ( $1.1-2.32 \times 10^5$  cells) and the amount of 2 g of the collected tissue does not enhance the bone formation and that requires the further testing. The evaluation of using stem cells in oral surgery is carried on by numerous research centres. Our results may confirm the need of culturing preosteoblasts *in vitro* before colonizing the grafts (24).

At that point in time, the essential outcome of the study was the lack of significant difference between the experimental biomaterial and positive control. BioOss Collagen is unquestionably a material with proven clinical efficacy (19-21, 25-28). It is unarguable difficult to extrapolate the long-range osteogenic potential of our experimental allogenic

material on the basis of 4 month study. The fact of initial disintegration of the particles is somehow promising. Our intention was to design a completely resorbable material which stimulates the bone formation and is replaced by autogenous bone without remnants.

There are currently contrary opinions on the resorption rate of available bone grafts. Many studies show the incomplete replacement by the autogenous bone because of the lack of osteoinduction and osteoproliferative properties (27, 29, 30). There are a few others which document the biodegradability even the xenogenic grafts with bone remodeling due to osteoplastic activity (31, 32).

In spite of that, the severe acute inflammation and granulomatous reaction occurred in one of the animals (sheep no. 1, BO). It should be stressed that high biocompatibility of both biomaterials was observed in all other cases. Most likely, the undesirable reaction was due to wound infection just after the surgery. The accompanying a foreign body-type reaction and the presence of multinucleated giant cells which markedly inhibit new bone formation was not related to the implantation of the bone substitute.

High failure ratio of implantation in sheep was of course described in literature before (33). In spite of that, sheep is still a valuable model for human bone turnover and remodeling activity (12, 29, 34). However, their special oral biomechanics inherent to their constant ruminant activity accounted for a high degree of the reported graft failures. Important adaptations to the implantation technique and postoperative management is necessary to use sheep as an animal for future oral implant related experiments.

In the histopathological assessment, the following facts were observed: visible bone remodeling area with an active presence of osteoblasts and singular osteoclasts on its verges. In the sites of mesenchymal remodelling there were ossification areas with active participation of osteoblasts. Most often the features of passive hyperemia and reactive fibrosis around small bone structures as well as fibrosis of perivascular parenchyma without traits of ossification could be observed.

*In vivo* tests gave the results that confirmed favorable osteogenetic abilities of both biomaterials, CH/TCP/Al<sub>3</sub> and BO. The relevant beneficial influence of using the adipose derived stem cells in GBR was not confirmed in this model.

## REFERENCES

1. Khor E., Lim L.Y.: *Biomaterials* 24, 2339 (2003).
2. Kim I.Y., Seo S.J., Moon H.S., Yoo M.K., Park I.Y. et al.: *Biotechnol. Adv.* 26, 1 (2008).
3. Ravi Kumar M.N.V., Muzzarelli R.A.A.: *Chem. Rev.* 104, 6017 (2004).
4. Shyh Ming Kuo, Shwu Jen Chang, Cheng-Chie G., Lan C.W., Cheng W.T., Yang C.Z.: *J. Appl. Polymer Sci.* 112, 3127 (2009).
5. Li Z., Ramay H.R., Hauch K.D., Xiao D., Zhang M.: *Biomaterials* 26, 3919 (2005).
6. Brandl F., Sommer F., Goepferich A.: *Biomaterials* 28, 134 (2008).
7. Drury J.L., Mooney D.J.: *Biomaterials* 24, 4337 (2003).
8. Łukomska-Szymańska M., Brzeziński P.M., Zieliński A., Sokołowski J.: *Folia Histochem. Cytobiol.* 48, 339 (2010).
9. Pagni G., Pellegrini G., Giannobile W.V., Rasperini G.: *Int. J. Dent.* 2012, 151030 (2012).
10. Horovitz R.A., Mazor Z., Foitzik C., Prasad H., Rohrer M., Palti A.: *Titanium* 1, 1 (2009).
11. Bojar W., Kucharska M., Ciach T., Koperski Ł., Jastrzębski Z., Szałwiński M.: *J. Biomater. Appl.* 28, 1060 (2013).
12. Pearce A.I., Richards R.G., Milz S., Schneider E., Pearce S.G.: *Eur. Cell. Mater.* 13, 1 (2007).
13. Bruder S.P., Kurth A.A., Shea M., Hayes W.C., Jaiswal N., Kadiyala S.: *J. Orthop. Res.* 6, 155 (1998).
14. Newman E., Turner A.S., Wark J.D.: *Bone* 16, 277 (1995).
15. Arvidson K., Abdallah B.M., Applegate L.A., Baldini N., Cenni E. et al.: *J. Cell. Mol. Med.* 15, 718 (2011).
16. Hsu S., Whu S.W., Tsai C.L., Wu Y.H., Chen H.W., Hsieh K.H.: *J. Polym. Res.* 11, 141 (2004).
17. Bojar W., Kucharska M., Bubak G., Ciach T., Koperski Ł. et al., *Acta of Bioengineering and Biomechanics* 14, 39 (2012).
18. Koźlik M., Wójcicki P., Rychlik D.: *Dent. Med. Probl.* 48, 547 (2011).
19. Markowska J., Radwan-Oczko M., Ziętek M.: *Polim. Med.* 35, 1 (2005).
20. Ciechowicz K.: *Prot. Stom.* 52, 273 (2002)
21. Artzi Z., Nemcovsky H., Tal H.: *Int. J. Periodontics Restorative Dent.* 21, 395 (2001).
22. Del Fabbro M., Testori T., Francetti L., Weinstein R.: *Int. J. Periodontics Restorative Dent.* 24, 565 (2004).
23. Bunnell B.A., Flaatt M., Gagliardi C., Patel B., Rippol C.: *Methods* 45, 115 (2008)
24. Wojtowicz A., Perek J., Urbanowska E., Kamiński A., Olender E., Jodko M.: *Dent. Med. Probl.* 50, 20 (2013).



25. Mendonca T.A., Conz M.B., Barros T.C., Sena L.A., Soares G.A., Granjeiro J.M.: *Braz. Oral Res.* 22, 5 (2008).
26. Kozakiewicz M., Marciniak-Hoffman A., Denkowski M.: *Dent. Med. Probl.* 46, 384 (2009).
27. Maiorana C., Redemagni M., Rabagliati M.: *Int. J. Oral Maxillofac. Implants* 15, 873 (2000).
28. Browaeys H., Bouvry P., Bruyn H.: *Clin. Implant Dent. Relat. Res.* 9, 166 (2007).
29. Paknejad M., Emtiaz S., Rokn A., Islamy B., Safiri A.: *Implant Dent.* 17, 471 (2009).
30. Skoglund A., Hising P., Young C.: *Int. J. Oral Maxillofac. Implants* 12, 194 (1997).
31. Aaboe M., Schou S., Hjorting-Hansen E.: *Clin. Oral Implants Res.* 11, 422 (2000).
32. Wetzel A.C., Stich H., Caffesse R.G.: *Clin. Oral Implants Res.* 6, 155 (1995).
33. Vlaminc L., Gorski T., Huys L., Saunders J., Schacht E., Gasthuys F.: *Implant Dent.* 17, 439 (2009).
34. Estaca E., Cabezas J., Uson J., Sanchez-Margallo F., Morell E., Latorre R.: *Clin. Oral Implants Res.* 19, 1044 (2008).

*Received: 1. 12. 2014*